



# Filtek™

Universal Restorative

## About the Case

The patient presented unaesthetic black triangles in the upper anterior and lower anterior sextants. He had recently completed orthodontic treatment to address the black triangles and was disappointed that the orthodontic treatment actually worsened the aesthetic dilemma. He was looking for a conservative solution to close his black triangles.

## Challenge

The patient was congenitally missing tooth No. 26. The black triangles were moderate to large in size. The challenge was to close the spaces and create anatomic tooth contours and widths and proper verticality of contact lengths. 3M™ Filtek™ Universal Restorative shade A1 was used, along with a Bioclear® prescriptive Black Triangle Kit.

## Outcome

The black triangles were closed with a minimally invasive additive technique (no tooth reduction) using 3M™ Filtek™ Universal Restorative. It masked the dark interdental spaces nicely. Restorations blended well with the natural tooth colour, and the restorations had a natural-looking polish. Bioclear®'s patented anatomic matrices enabled predictable, atraumatic outcomes with subgingival contour changes.



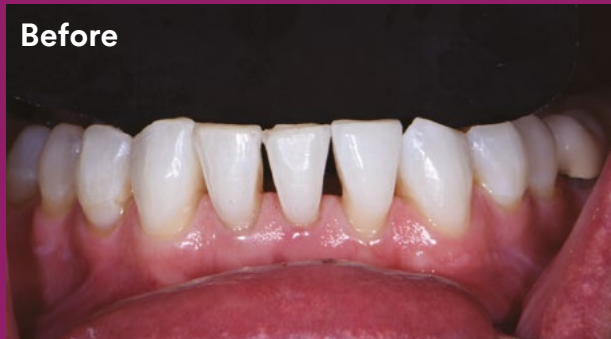Clinical Case

Dr. Jihyon Kim

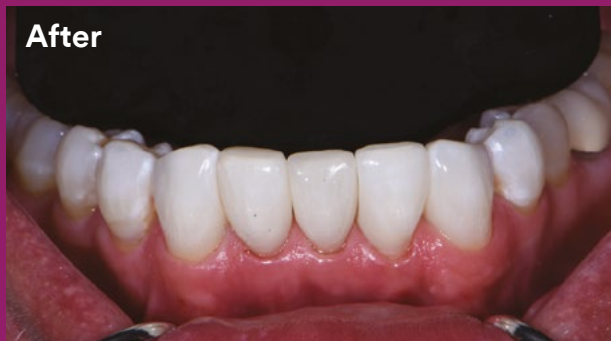## Prescriptive and predictable black triangle treatment

Clinical dentistry and photography by Dr. Jihyon Kim

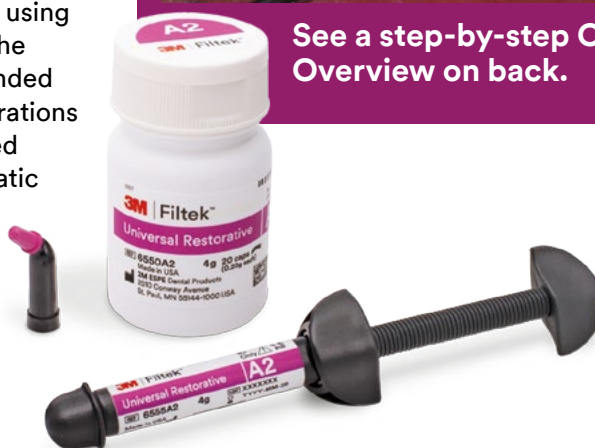Before



After



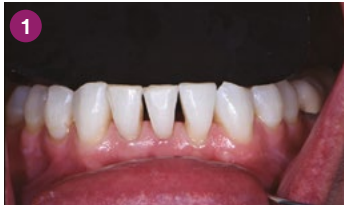See a step-by-step Case Overview on back.



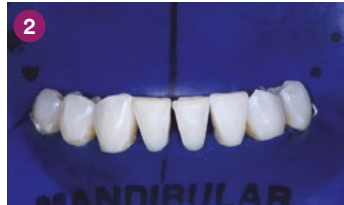## About Dr. Jihyon Kim

Dr. Kim is one of the world's leading experts in injection-molded composite dentistry. She maintains patient practices in Bellevue and Tacoma, Washington, with an emphasis on aesthetic smile rejuvenation via injection-molded direct composite dentistry. Dr. Kim created the Smile Design Gauge, a multifunction clinical tool for predictable chairside smile design, and developed a unique discing protocol for shaping aesthetic injection overmolded tooth forms. She has published multiple articles on the Bioclear® Method, Chairside Smile Design, Posterior Quadrant Strategies for Direct Composites, Restorative Orthodontics and Injection Molding.

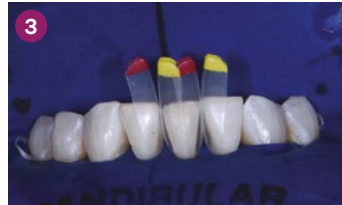# Case Overview



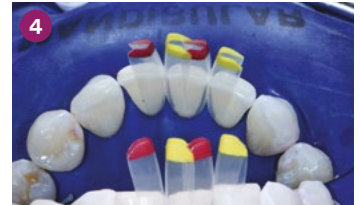**INITIAL SITUATION:** Preoperative photo with contrast background showed the dimensions of the black triangles resulting from congenitally missing tooth No. 26 and adult orthodontic treatment.



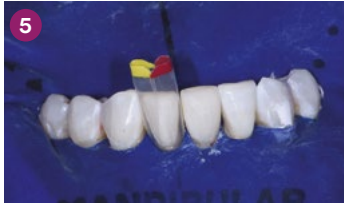Rubber dam isolation was done for field control and soft tissue retraction. Next, teeth were dried and disclosing solution was applied to reveal biofilm, which was then removed with aluminum trihydroxide in a Bioclear® Blaster.



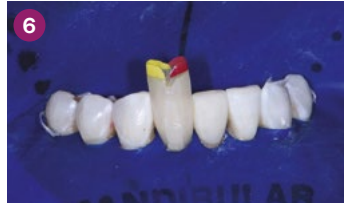Black triangle small incisor matrices were placed. Tooth No. 24 was injection molded first. A mix of matrices were selected with a black triangle gauge prior to isolation, to close spaces and maintain vertical contacts without canting.



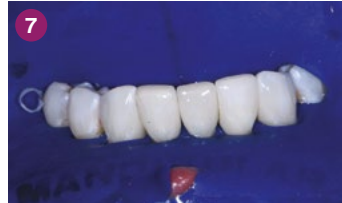Lingual view with matrices placed showed the change in tooth contour that needed to be obtained to achieve adequate space closure.



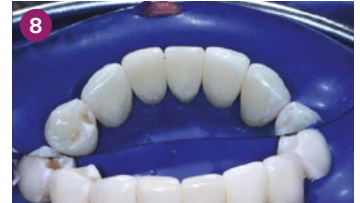Injection molding and shaping of tooth No. 24 was completed. Tooth No. 25 was then matrixed and readied for injection molding.



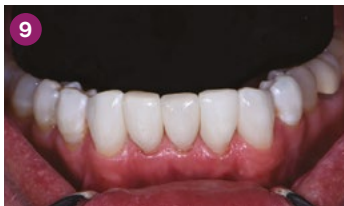Injection molding completed on tooth No. 25. The excess volume created a monolithic inner core. The outer layer was removed, and the inner core was shaped with 3M™ Sof-Lex™ Finishing and Polishing Discs.



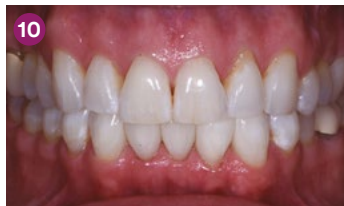Labial view of the completed case showed four black triangles were closed between tooth Nos. 22 and 27.



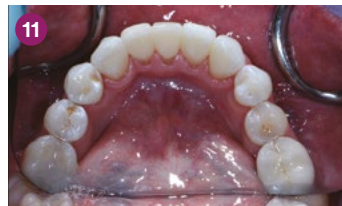Lingual view of completed case showed proper anatomic shapes and smooth polish, which would feel natural to the tongue.



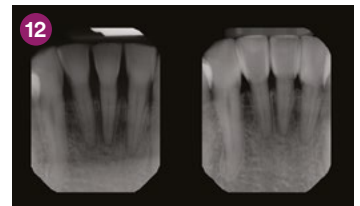
Immediate postoperative view with contrast. Note the closure of spaces, atraumatic tissue condition and tissue adaptation to the new shapes.



Retracted views. Teeth were still dehydrated, but natural shade blending with 3M™ Filtek™ Universal Restorative was already noticeable.



Immediate postoperative lingual view showed atraumatic and favorable tissue response and adaptation.



Preoperative (left) and postoperative (right) radiographs revealed intimate adaptation and infinity edge margins that lend to the favorable tissue responses.

**FINAL RESULT:** The black triangles were closed beautifully. The restorations had both natural-looking tooth contours and colour.

Refer to Instructions for Use (IFU) for complete product information.

To learn more:

**3M.com.au/FiltekUniversal**  
**3M.co.nz/FiltekUniversal**

For information about Bioclear® visit: [www.bioclearmatrix.com](http://www.bioclearmatrix.com):



## 3M Oral Care

3M Australia Pty Limited  
Building A, 1 Rivett Road  
North Ryde, NSW 2113  
Ph: 1300 363 454  
[www.3M.com.au](http://www.3M.com.au)

3M New Zealand Limited  
94 Apollo Drive  
Rosedale, Auckland 0632  
Ph: 0800 80 81 82  
[www.3M.co.nz](http://www.3M.co.nz)

3M, Filtek and Sof-Lex are trademarks of 3M. All other trademarks are not trademarks of 3M. © 3M 2019. All rights reserved.